

# Pneumocephalus and Neurologic Deficit Due to Neck Stab Wound in a Twenty Nine-Year-Old Man

Toktam Mohammadi Rana,<sup>1</sup> Behrang Rezvani Kakhki,<sup>1\*</sup> Nasim Choobdari,<sup>1</sup> and Hosein Zakeri<sup>1</sup>

<sup>1</sup>Department of Emergency Medicine, Faculty of Medicine, Mashhad University of Medical Sciences, Mashhad, Iran

\*Corresponding author: Behrang Rezvani Kakhki, Edalatian Emergency Department, Imamreza Hospital, Razi Squire, Mashhad, Iran. E-mail: rezvanikb@mums.ac.ir

Received 2016 September 16; Revised 2016 November 04; Accepted 2016 November 16.

## Abstract

**Introduction:** The presence of air within the intracranial cavity, due to the entry of air secondary to an abnormal communication after a dural tear, is defined as pneumocephalus and intraventricular pneumocephalus also known as pneumoventricle. Obviously, common etiologies of pneumocephalus are head injury and cranial surgery. Also, less common non-traumatic causes of pneumocephalus are neoplasm or from a gas-forming organism infection. Although pneumocephalus after spinal penetrating injuries is rare, it was reported. The object of this report is to describe the case of patient with pneumoventricle after neck spinal stab wound.

**Case Presentation:** A 29-year-old man presented to ED with complaint of two stab wounds, one of them was located at the right back chest and the other at the midline neck. Because of the respiratory distress and decreased breath sounds, after taking a chest X-ray, we realized hemothorax in right hemithorax and placed the chest tube in ED. In addition, in requested neck CT scan, there was a diffuse air in neck spine that spread to his brain. Furthermore, neurologic examination showed weakness in left leg motor function and loss of pain and temperature sensation in the other leg, which was based on brown-sequard syndrome. Mentioned patient admitted in neurosurgery department for further follow-up.

**Conclusions:** Pneumoventricle is rare but it can be established after spinal trauma. By awareness of such possibility, accurate diagnosis by clinical examination and imaging is essential for these types of injuries

**Keywords:** Pneumocephalus, Pneumoventricle, Spine, Stab Wound

## 1. Introduction

Pneumocephalus is commonly established after neurosurgical procedure due to iatrogenic spinal dura tear, but it can also be the result of trauma (1). Post traumatic fractures of temporal bone air cells or paranasal sinuses or skull base can cause dura lacerations and pneumocephalus (1, 2). Spinal dura tears after stab wounds can also cause to presence of intracranial gas. Three membranes called meninges cover the brain and spinal cord (3). Subdural space is a space between dura mater and arachnoid mater which is connected to the floor of the third ventricle and intracranial space, also, it is wider in cervical region (3, 4). Although pneumoventricle caused by penetrating spinal injury is rare (5), it can be assumed that pneumoventricle may have resulted from air entering the subdural space and lead to the intracranium (1). The entrance of air in to the cranial cavity is due to one of two possible mechanisms (6, 7): 1- The leakage of cerebral spinal fluid causes the negative intracranial pressure and air enters to equilibrate the pressure differential. 2- The valve mechanism at the wound or fracture site, through which air enters the subarachnoid space but not exits (5, 6). Formation of pneumoventricle may occur immediately or be delayed. Signs and symptoms are often vague and nonspe-

cific. A patient may complain of a headache, dizziness, nausea and vomiting, lethargy, an altered mental status, and the meningism (1).

In addition, penetrating trauma to the spine can injure spinal cord too. Generally, spinal cord injury divided to primary and secondary injuries. The spinal cord may be injured primarily by neural elements transection which is irreversible. Secondary spinal cord injury is a neurologic deficit that may progress over hours and often not presented immediately (8). Other classification is complete and incomplete. A complete spinal cord lesion is a total loss of motor and sensation power distal to the level of spinal injury. Incomplete spinal injuries are classified as one of these syndromes: the central cord syndrome, the anterior cord syndrome and Brown-Sequard syndrome. The central cord syndrome is the most common in which upper extremities are more affected than the lower. The anterior cord syndrome is characterized by paralysis below the site of spinal cord trauma but the functions of posterior column including touch, vibration and position sensations are preserved (9). Finally, the hemisection of the spinal cord causes Brown-Sequard syndrome that usually results from penetrating trauma. In this injury, ascending dorsal columns, the descending lateral corticospinal tracts

which both cross in the medulla, and the ascending lateral spinothalamic tracts, are disrupted (10). The characteristics of mentioned syndrome are the loss of ipsilateral vibration and position sense also motor paralysis but loss of the contralateral temperature and pain sensation distal to the location of spinal cord injury. Virtually, the functions of bowel and bladder are maintained (9). We present the case that had knife injury to his neck spine developing into pneumoventricle and the plus signs of Brown-Sequard syndrome.

## 2. Case Presentation

A previously healthy 29-year-old man visited our emergency department who sustained two stab wounds. One wound located at the right posterior thorax and the other was parallel at the third cervical spine. In the moment of monitoring the patient, in the primary survey, his airway was intact and we fixed the neck collar for him. He had mild respiratory distress with decreased respiratory sounds on his right hemithorax without the signs and symptoms of sucking wound or tension pneumothorax. He was hemodynamically stable and no hemorrhage detected from wounds. Although he was fully conscious but the important fact was that he could not flex his left knee completely. In continues, there was not any pathologic findings in log roll and rectal exam. After initial steps such as taking IV line and blood samples, in next clinical examinations, the only abnormality was the loss of temperature and pain sensation in his right leg, in addition, movement disorder and loss of position and vibration senses in the left leg, that were emphasized the diagnose of Brown-Sequard syndrome. CXR and neck CT scan was requested. The evidence of right hemothorax was obvious in the CXR, so we placed the chest tube that was leading to evacuate nearly 300 cc blood. The obtained neck CT scan revealed intra spinal air spread to the brain in order to dura tear vice versa any spinal bone fracture. We positioned the patient in semi seating with neck Philadelphia collar and supplemental oxygen was ordered. The patient admitted in neurosurgery ICU with surgery consultant for close observation in order to further treatment and prevent other complications. In conclusion, the dura mater was repaired the day after trauma and chest tube was emitted after three days. During the hospitalization, the patient remained conscious with the GCS of 15/15 and the pneumoventricle did not extent, but the neurologic deficits due to Brown-Sequard lesion were sustained. Finally, he released after nine days. In next follow ups, the patient had improved significantly and we realized that his neurologic symptoms cured completely during two months thereafter.

## 3. Discussion

Formation of pneumoventricle may occur immediately or be delayed and as it was mentioned, signs and symptoms are often vague and nonspecific. A small amount of the air is asymptomatic and misleading and resolves spontaneously after a few days, however, high inspired oxygen concentration can accelerated its absorption (11). Surgical intervention in order to repair dura mater defects should only be performed when there is neurological deficit, persistent CSF leakage or infection (1, 12). Simple X ray, CT scan or MRI diagnose the air in spinal and cranial space. CT scan is a specific, highly sensitive and cost-effective tool in the diagnosis of this condition (6). Even 0.5 cc of air in the intracranial compartment can be detected by CT scan (6).

Neurological injury caused by penetrating spinal trauma is a Brown-Sequard lesion in the majority. Brown-Sequard syndrome includes ipsilateral weakness with contralateral loss of pain and temperature sensation which has a relatively good prognosis for spontaneous recovery (10, 13). In patients with Brown-Sequard syndrome, almost full motor and sense functions may recover within 6 months after trauma (13) just as our patient who completely recovered after approximately two months.

Moreover, the recovery prognosis seems more acceptable in patients who have blunt trauma rather than penetrating injury (13).

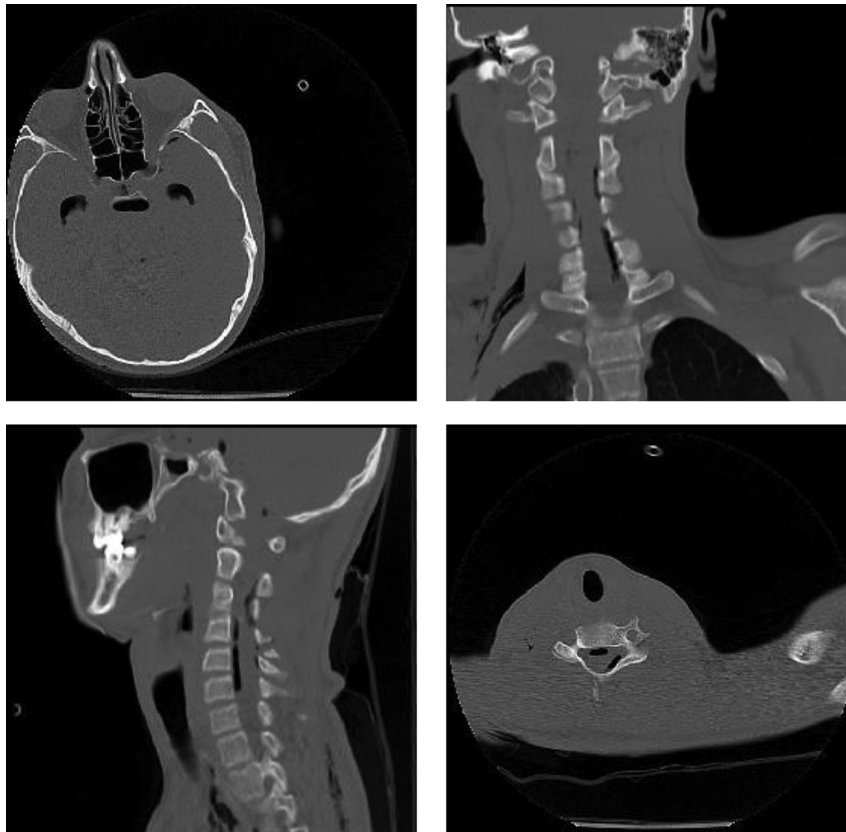
In conclusion, the goal of these authors with this case report is to bring this issue to the attention of emergency specialists to remember of the potential pneumocephalus after spinal stab wounds. Clinical examination and radiographic imaging are essential for these injuries. In trauma setting, close observation and if necessary, surgical intervention detect and correct neurological compromise, in addition, they allow for the most appropriate management of these injuries (1).

## Footnote

**Authors' Contribution:** Behrang Rezvani Kakhki developed the original idea and the protocol, abstracted and analyzed data, wrote the manuscript, and was the guarantor; Toktam Mohammadi Rana and Nasim Choobdari and Hosein Zakeri contributed to the development of the protocol, abstracted data, and prepared the manuscript

## References

1. Yun JH, Kim YJ, Yoo DS, Ko JH. Diffuse pneumocephalus : a rare complication of spinal surgery. *J Korean Neurosurg Soc.* 2010;48(3):288-90. doi:10.3340/jkns.2010.48.3.288. [PubMed: 21082062].



**Figure 1.** Left upper: axial cut of brain CT scan, pneumoventricle; right upper: coronal cut of neck CT scan: air in spinal column; left lower: sagittal cut of neck CT scan, air in spinal column; axial cut of neck CT scan, air in spinal column

2. Cuellar DC, Saenz HY, Fraino A. Pneumocephalus: Beyond its traumatic cause. *European Soci Radiol.* 2015.
3. Kim YD, Lee JH, Cheong YK. Pneumocephalus in a patient with no cerebrospinal fluid leakage after lumbar epidural block - a case report. *Korean J Pain.* 2012;25(4):262-6. doi: [10.3344/kjp.2012.25.4.262](https://doi.org/10.3344/kjp.2012.25.4.262). [PubMed: [23091688](https://pubmed.ncbi.nlm.nih.gov/23091688/)].
4. Ajar AH, Rathmell JP, Mukherji SK. The subdural compartment. *Reg Anesth Pain Med.* 2002;27(1):72-6. [PubMed: [11799508](https://pubmed.ncbi.nlm.nih.gov/11799508/)].
5. Valente MA, Bender EA. Severe pneumocephalus after penetrating injury to the lumbar spine. *IJCRI.* 2012;3(4):23-5.
6. Rahamimov N, Mulla H, Freiman S. Cerebrospinal fluid leakage and pneumocephalus secondary to spine stab wounds. *J Orthop Traumatol.* 2010;11(1):57-9. doi: [10.1007/s10195-009-0070-6](https://doi.org/10.1007/s10195-009-0070-6). [PubMed: [19915795](https://pubmed.ncbi.nlm.nih.gov/19915795/)].
7. Bunc G, Roskar Z, Vorsic M. Pneumocephalus secondary to a neck stab wound without neurologic injury in a 13-year-old girl. *Pediatr Neurosurg.* 2001;34(5):239-41. [PubMed: [11423773](https://pubmed.ncbi.nlm.nih.gov/11423773/)].
8. Guthkelch AN, Fleischer AS. Patterns of cervical spine injury and their associated lesions. *West J Med.* 1987;147(4):428-31. [PubMed: [3318136](https://pubmed.ncbi.nlm.nih.gov/3318136/)].
9. Maroon JC, Ablu AA. Classification of acute spinal cord injury, neurological evaluation, and neurosurgical considerations. *Crit Care Clin.* 1987;3(3):655-77. [PubMed: [3332218](https://pubmed.ncbi.nlm.nih.gov/3332218/)].
10. Kobayashi N, Asamoto S, Doi H, Sugiyama H. Brown-Sequard syndrome produced by cervical disc herniation: report of two cases and review of the literature. *Spine J.* 2003;3(6):530-3. [PubMed: [14609700](https://pubmed.ncbi.nlm.nih.gov/14609700/)].
11. Ahn S, Ko YS, Lim KS. Ventricular pneumocephalus with meningitis after lumbar nerve root block. *Case Rep Emerg Med.* 2013;2013:640185. doi: [10.1155/2013/640185](https://doi.org/10.1155/2013/640185). [PubMed: [23762659](https://pubmed.ncbi.nlm.nih.gov/23762659/)].
12. Goncalves MB, Nunes CF, Melo Jo Jr, Guimaraes RD, Klescoski J Jr, Landeiro JA. Tension pneumoventricle after resection of a fourth ventricle choroid plexus papilloma: An unusual postoperative complication. *Surg Neurol Int.* 2012;3:116. doi: [10.4103/2152-7806.102325](https://doi.org/10.4103/2152-7806.102325). [PubMed: [23226603](https://pubmed.ncbi.nlm.nih.gov/23226603/)].
13. Miranda P, Gomez P, Alday R, Kaen A, Ramos A. Brown-Sequard syndrome after blunt cervical spine trauma: clinical and radiological correlations. *Eur Spine J.* 2007;16(8):1165-70. doi: [10.1007/s00586-007-0345-7](https://doi.org/10.1007/s00586-007-0345-7). [PubMed: [17394028](https://pubmed.ncbi.nlm.nih.gov/17394028/)].